

Intriguing Tuberous Sclerosis: Clinico-Radiological Mismatch

Sonali Singh¹ and Rahul Sinha^{2*}

¹Department of Pediatrics, Institute of Neurosciences, Kolkata, India

²Department of Pediatrics and Pediatric Neurology, Command Hospital, Panchkula, India



***Corresponding author:** Rahul Sinha, Department of Pediatrics and Pediatric Neurology, Command Hospital, Chandimandir, Panchkula, Haryana 134114, India.

E-mail: drrahul_2000@yahoo.com



Article Type: Clinical Image

Compiled date: April 07, 2022

Volume: 1

Issue: 1

Journal Name: Annals of Neurological Research and Studies

Publisher: Infact Publications LLC

Journal Short Name: Ann Neur Res Stud

Article ID: INF1000167

Copyright: © 2022 Rahul Sinha. This is an open access article distributed under the terms of the Creative Commons Attribution 4.0 International License (CC BY-4.0).



Keywords: Tonicclonic seizures; Epileptic spasms; Angiofibromas; Cortical tubers



Cite this article: Singh S, Sinha R. Intriguing tuberous sclerosis: clinico-radiological mismatch. Ann Neur Res Stud. 2022;1(1):1-2.

Clinical Image

A twelve year old girl presented with drug refractory epilepsy, significant behavioral issues and intellectual disability. She had three hypo pigmented patches on face. At four months of age she developed epileptic spasms, which resolved by two years. Thereafter she developed focal as well as generalized tonicclonic seizures. EEG showed right frontal focus. Her CT head ([Figure 1a](#) and [Figure 1b](#)) and MRI Brain ([Figure 1c](#)) showed five calcified tubers and few calcified Sub Ependymal Nodules (SENS).

A three year old neuro-typical boy presented with multiple facial angiofibromas and shagreen patches on trunk. He never had seizures or any behavioral issues. His MRI brain ([Figure 2a–Figure 2d](#)) showed Subependymal Giant cell Astrocytoma (SEGA), multiple SENS, bilateral cystic and non-cystic cortical tubers. EEG showed no epileptiform discharges.

More the MRI abnormalities, usually more severe the clinical phenotype is expected to be. However, it is not always true. Such an extensive cutaneous and imaging findings would predict TSC2 mutation, high seizure burden and poor cognitive outcome [1,2]. In this child absence of seizure worked in his favour despite extensive imaging findings which otherwise predict poor outcome.

Conflict of Interest

The authors declare no potential conflicts of interest with respect to the research, authorship, and/or publication of this article. Informed consent was obtained for this publication.

References

1. Chu-Shore CJ, Major P, Montenegro M, Thiele E. Cyst-like tubers are associated with TSC2 and epilepsy in tuberous sclerosis complex. *Neurology*. 2009;72(13):1165–1169.
2. Northrup H, Aronow ME, Bebin EM, Bissler J, Darling TN, de Vries PJ, et al. Updated international tuberous sclerosis complex diagnostic criteria and surveillance and management recommendations. *Pediatr Neurol*. 2021;123:50–66.

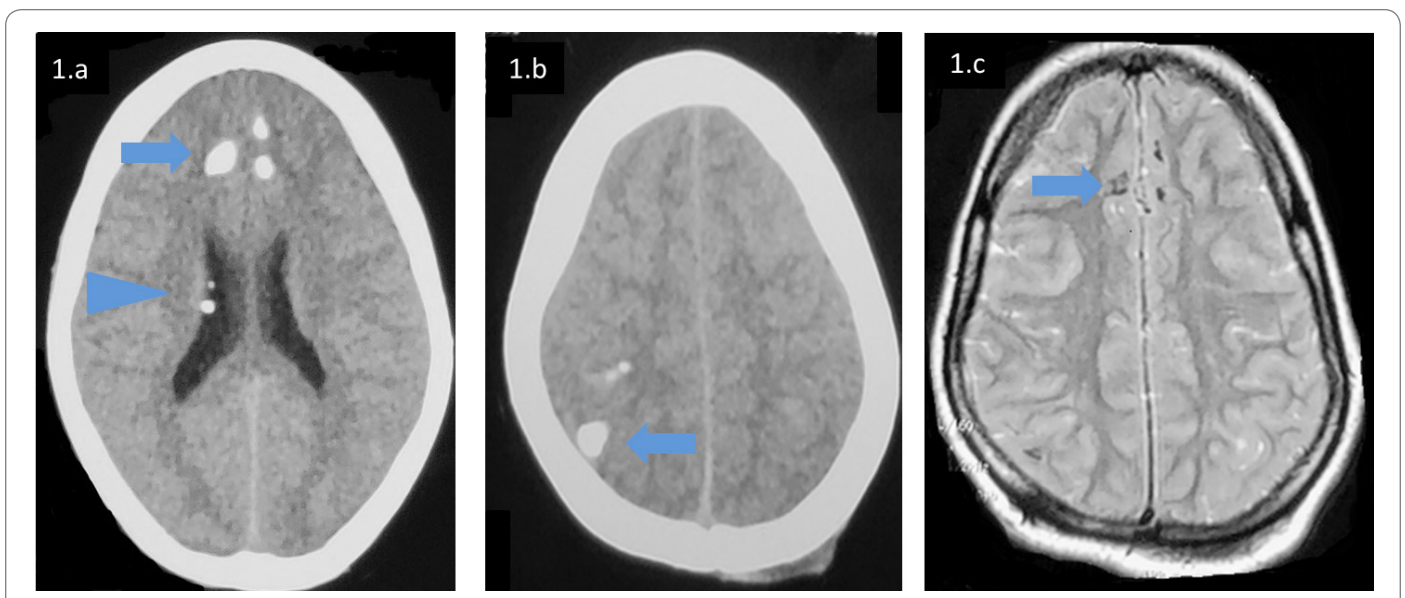


Figure 1: CT Head of first child showed calcified tubers (1a, 1b, blue arrow) and calcified SENs (1a, blue arrow head), MRI Brain (1c) showed T2 hypointense (calcified) tubers.

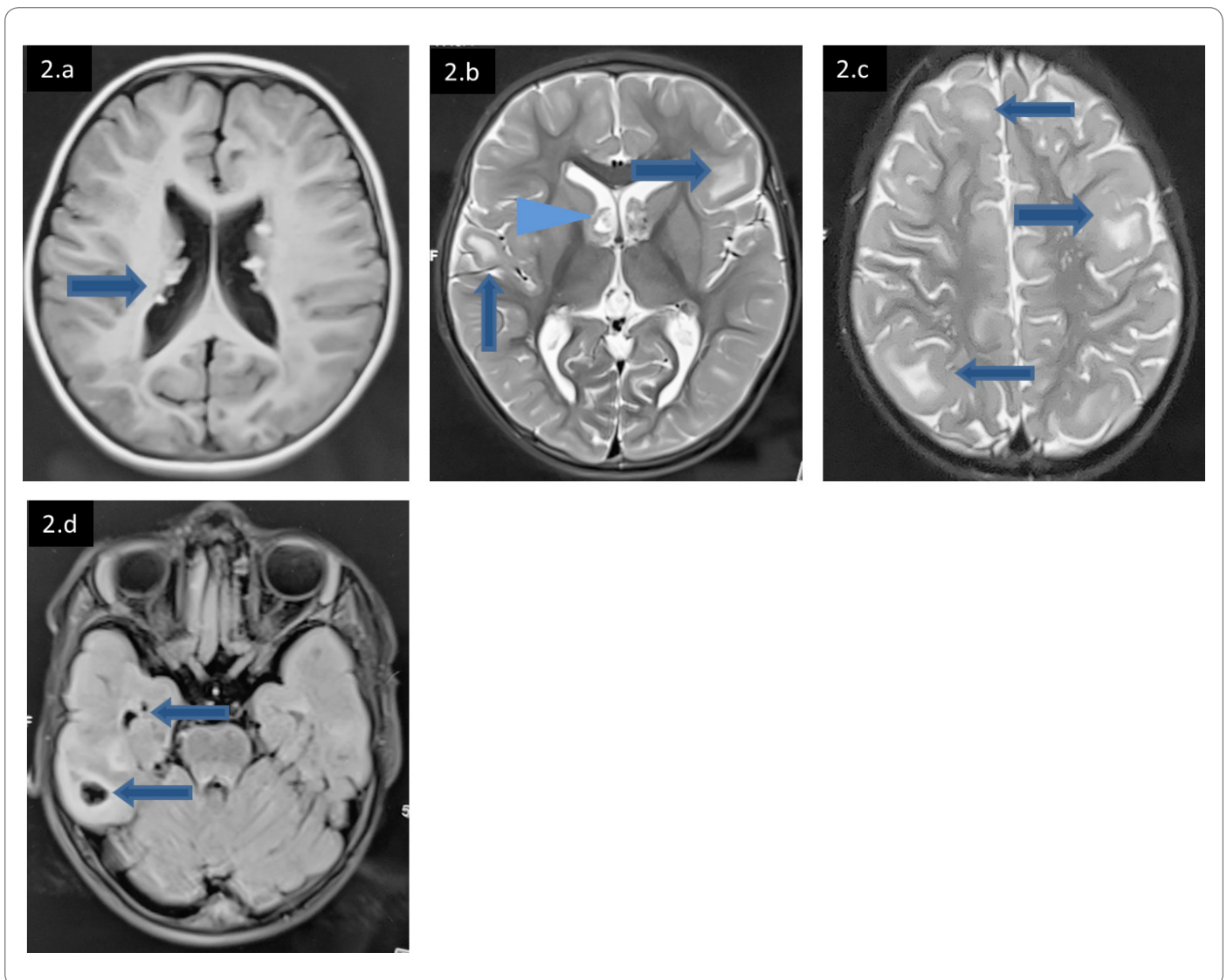


Figure 2: MRI brain of second child shows SENs (2a), SEGA at the level of foramen of Monro (2b, blue arrow head), multiple T2 hyperintense cortical tubers (2c, blue arrow), FLAIR sequence (2d) shows cystic cortical tubers in right temporal lobe.